



VETERINARY SURGICAL CENTERS

Welcome to our summer edition 2009 newsletter– we are pleased to bring our announcements, education pieces and animal and practice interest notes for you to enjoy and pass on to your staff. To receive this newsletter in e-form, please email our business office: deltasurg@yahoo.com with your request.

Notable Changes: Veterinary Surgical Centers of the Delta will be shortening its business office name to Veterinary Surgical Centers. This change was made to accurately reflect the fact that we are performing referral veterinary surgery all over the bay area including Berkeley, Dublin, Walnut Creek, the Central Valley, as well as along the Delta by-ways. Our mobile surgical services division will continue under the Veterinary Surgical Centers of the Delta logo and name.

Notable Moves: Our referral veterinary surgical service and operation in Berkeley has a new home! On June 8, 2009 Veterinary Surgical Centers-Berkeley, with Drs. Kim Carlson and John Haburjak at the helm, moved into a referral-only complex with the historic PETS afterhours emergency service (<http://www.berkeleypets.org/>)! With the exciting added internal medicine services of Dr. Jennifer McCown and oncology services of Dr. Kathy Andres, we are pleased to offer comprehensive, around-the-clock, seamless referral veterinary services. Please visit all of us at 1048 University Avenue in Berkeley or call 510-548-6684.

Notable Additions: Veterinary Surgical Centers is pleased to announce that we are continuing to grow! Dr. Alastair R. Coomer, a New Zealander with a professed love of road cycling, his wife, and all things edible will be joining Veterinary Surgical Centers at the conclusion of his University of Florida residency later this fall. Please see the enclosed insert for his profile.

What you can continue to expect from Veterinary Surgical Centers:

- Direct contact with a VSC surgeon – 7 days a week for consultation, case support and for scheduling referral and mobile surgery. (925-201-3400 or 510-595-4600)
- Electronic case and radiographic case consultation 7 days a week. Deltasurg@yahoo.com
- 24 hour/day surgery by a completely trained veterinary surgeon. Residents will not be performing surgery on your referrals.
- Mobile veterinary surgical services by a skilled and experienced surgeon with ‘low-impact’ on your daily staff and procedural operations with most surgeries (including TPLO) performed in less than 2 hours.

To have the experience of the VSCD
High-Tech High-Touch commitment,
Give us a try...



SUMMARY OF SERVICE OFFERINGS

WHAT CAN VSCD OFFER YOUR FACILITY?

- Board-certified surgical expertise
- Receiving referrals for advanced consultation, diagnostic and surgical services
- Providing surgical services at your facility with minimal impact on your daily operations and resources
- Offering telephone or electronic (email) consultations
- Giving on-site continuing education lectures personalized to the needs of your staff
- Providing complimentary informational brochures and pamphlets for use internally and for clients

NOTABLE NEWS

VSCD in cooperation of North America's newest veterinary college (Western University) has agreed to host a number of fourth year veterinary students during their 'core' surgery rotations. As an Associate Professor our working surgeons are using clinical cases and intra-operative teaching opportunities to enrich the educational exposure of our up and coming veterinarians. VSCD is proud to be part of growing our honorable profession



MEET OUR SURGEONS

John J. Haburjak • Kimberly Carlson • Heather Towle



Welcome Dr. Coomer!



Alastair Coomer graduated from Massey University (New Zealand) in 2003 and practiced in New Zealand as a general practitioner for 18 months before pursuing surgical specialization. He completed a rotating internship at the Ontario Veterinary College (Canada), before being accepted into the Small Animal Surgery Residency Program at the University of Florida. During his surgical residency, Alastair also completed his Master of Science (Veterinary Science), receiving collegiate, national and international awards for his research and research presentations. His clinical interests include wound healing, reconstructive surgery, musculoskeletal surgical oncology, gastrointestinal and hepatobiliary surgery.

Outside of veterinary medicine, Alastair enjoys cycling (road, mountain, cyclocross), endurance multisport, rugby and Gator Football. Alastair and his wife Erin (also a veterinarian) love to travel locally and internationally. They have two badly behaved dogs: Gabby, an English Bulldog; and Nala, a Boxer-mix all the way from New Zealand.



FEATURED MEDICAL CASE


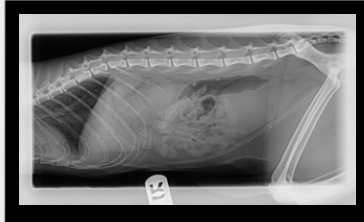
SURGICAL MANAGEMENT OF URETERAL STONES

"Bella" is a 3 year old spayed female Siamese cat who presented with a history of acute onset of pollakiuria, dysuria and hematuria. Radiographs and ultrasound diagnosed bilateral hydronephrosis and hydroureter secondary to ureteral stone obstruction. Significant laboratory values included BUN of 126 and creatinine of 10.6.

"Cleopatra" is a 10 year old spayed female Himalayan cat who presented with a history of chronic renal failure with acute decompensation. Ultrasound revealed left unilateral hydronephrosis and hydroureter secondary to ureteral stone obstruction. Relevant laboratory values included BUN of 62 and creatinine of 5.2.

...Featured Medical Case continued

Though their presentation differed, both cats were successfully treated with microscopic ureter surgery by Dr. Carlson. These patients underscore the need to perform thorough diagnostics when assessing kidney disease. Ureteral stones (which are almost always composed of calcium oxalate) may be present in as many as 25% of cats affected with chronic renal failure. Partial or complete ureteral obstruction will lead to the progressive loss of nephrons and consequent renal function: because it is essential that every effort be made to preserve nephrons in these patients both the obstruction and/or the underlying disease process must be addressed. Fixing the obstruction does not fix the underlying disease process. Since obstructive nephropathy is potentially correctible, it is important to recognize its occurrence before extensive and irreversible renal damage takes place. Other factors to consider include:

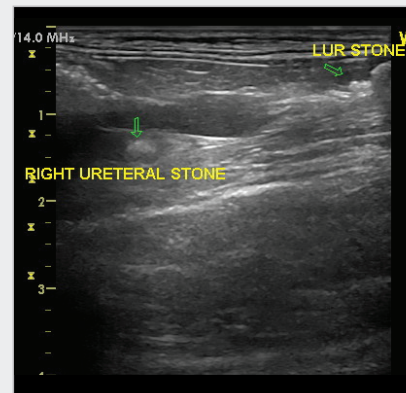
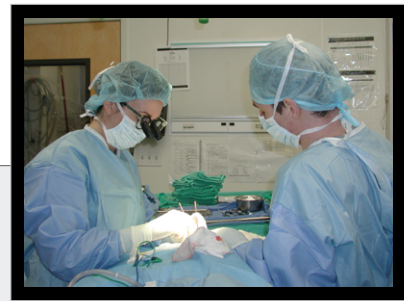

- Many cats with chronic kidney failure demonstrate relatively stable renal function over time: progressive declines in these values should prompt investigation of ureteral obstruction.
- The principle concern in managing uroliths in cats with renal disease is to minimize the risk that the urolith may cause further loss of renal function.
- Over time, the reversibility of obstructive renal injury declines: early detection maximizes the value of surgical intervention.
- In general, ureteroliths that are not associated with urinary obstruction and do not cause clinical signs can be left in place but should be monitored.
- Nephroliths, however, are rarely associated with obstruction unless they move into the ureter and most remain within the renal pelvis.
- Not every ureterolith requires surgical intervention. Some will move down the ureter and ultimately exit to the bladder. Evidence of progressive movement toward the bladder, with stable renal function, generally suggests delaying surgery.
- Surgical intervention should be based on contemporary alterations in renal structure and function using serial laboratory diagnostics and ultrasonography. If surgery is indicated, the precise technique is dictated by the location of the stone within the ureter.

NEWSROOM FEATURES

SPECIALIZED SKILL SET!

Dr. Kim Carlson is one of only a handful of veterinary surgeons who performs microvascular work. Her area of particular expertise includes the removal of ureteroliths in our feline patients. Recently Dr. Carlson performed this delicate work bilaterally in a young Siamese patient. If you believe a patient of yours may have a ureteral obstruction, please do not hesitate to call or email (deltasurg@yahoo.com) to discuss the inclusion criteria for this specialized surgery.



For more information on these cases or ureter surgery in general please contact Dr. Carlson.

Kimberly R. Carlson, DVM

Diplomate of the American College of Veterinary Surgeons

NEWSROOM FEATURES

FIXIN: TRAUMA FIXATION DEVICE

Veterinary Surgical Centers is pleased to announce that Dr. John Haburjak and Dr. Kim Carlson have added a new trauma fixation device. This new system referred to as 'Fixin' (www.traumavet.it) is a product designed after a human stainless steel-titanium coupling system which maintains the alignment of fractures and osteotomies with fewer screws – thus enhancing biologic healing – while making use of the tremendous biomechanical advantages of conical coupling (rather than screw fixation which requires friction and compression to achieve results). This new system has already begun to shift the paradigm of many of the age-old tenets of fracture fixation.



NEWSROOM FEATURES

SHO: CONFERENCE

In late February, Drs. Kim Carlson and John Haburjak attended an 'invitation-only' seminar in Boston, Massachusetts on a new elbow procedure to improve the quality of elbow comfort and limb use in specifically effected dogs with elbow dysplasia. This new technology referred to as SHO (sliding humeral osteotomy) is a tremendous advancement in the treatment of elbow disease and we invite you to look at this new procedure more closely in our academic interest article later in this newsletter.

PROFESSIONAL INTEREST ARTICLE

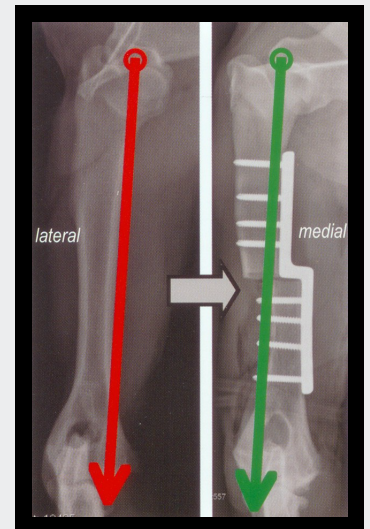
SLIDING HUMERAL OSTEOTOMY (SHO)

New Hope and New Treatment for Canine Elbow Dysplasia

Elbow dysplasia is a genetic disorder in which a fragmented coronoid process (FCP) is the most common manifestation. With an FCP there is generally a free osteochondral (bone chip) segment that has fragmented or fractured off within the joint. As importantly, there may be other elements of elbow dysplasia that affect the elbow simultaneously, in various degrees of severity: full-thickness cartilage erosion or cartilage loss (so called 'Medial Compartment Disease'), Un-united Anconeal Process, Osteochondrosis dissecans (OCD).

Diagnosis and Significance of Medial Compartment Disease

Generally, we recommend a combination of physical examination findings, x-rays, CT scans, and arthroscopy as a means of most completely and accurately assessing (staging) the condition of an elbow with elbow dysplasia. Depending on the severity of the condition, dogs with Medial Compartment Disease generally require more or less continuous use of anti-inflammatories, stem cell therapy, pain-relievers and acupuncture to preserve quality of life.



Total Elbow Replacement

Total elbow replacement may be indicated when cartilage damage has spread completely throughout the joint and is no longer limited to the medial compartment.

Sliding Humeral Osteotomy (SHO)

The Sliding Humeral Osteotomy (SHO) was experimentally derived in the Orthopedic Research Laboratory of the University of California, Davis in the late 1990's. The rationale of the SHO is based on an essentially similar procedure performed in the human knee. The SHO realigns the limb such that there is a shift of forces from the diseased medial compartment over to the healthier lateral compartment.

SHO – The Procedure

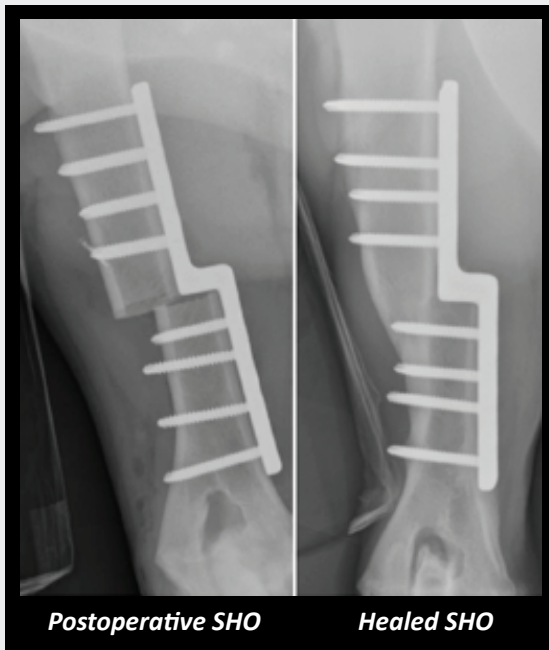First, we will perform elbow arthroscopy to better assess and characterize the cartilage quality. After the joint is treated a medial approach is made to the humerus. An osteotomy is made in the middle of the humerus and a bone plate with a 'step' and screws is applied such that as the screws tighten the two individual pieces of the humerus slide past one another resulting in an eccentrically loaded bone.

Clinical Experiences

Careful clinical studies have been performed^① to evaluate the efficacy of this procedure. The majority of dogs undergoing SHO have decreased lameness by 3 months post-operatively with many of the dogs exhibiting complete clinical soundness at 6 month post-operative. In nearly all patient cases, there was profound owner satisfaction with the outcome. This contrasts steeply with results obtained from medical management only with or without FCP removal.

SHO Surgeons

There are fewer than 50 trained veterinary surgeons currently certified for performing the SHO. VSCD surgeons, Dr. John Haburjak and Dr. Kim Carlson, are SHO-certified and we are pleased to offer this procedure as well as other diagnostic and treatment options for canine elbow dysplasia.



^① Fitzpatrick N, Yeadon R, et. al. Techniques of Application and Initial Clinical Experience with Sliding Humeral Osteotomy for Treatment of Medial Compartment Disease of the Canine Elbow. Vet Surg 38:261-278, 2009

RESOURCE CORNER

ASHLEY & CO.
THE FINEST PAW PRINT JEWELRY

www.ashleyandco.com

Unique human and pet

jewelry from the Bay Area's very own Vanessa Wensing, DVM!

www.pacocollars.com

Haute couture for your canine and feline (and people too!) companions from local leather and metal artist Ana Poe.



www.venividiclick.com

Local photographer, Inga Heuser brings an astounding passion and creativity to her work with pet owners and their furry companions.

FEATURED BROCHURE

MINIMALLY INVASIVE SURGERY: TECHNIQUES AND APPLICATIONS

We are very excited to highlight this issue's featured brochure describing minimally invasive surgical (MIS) methods and uses. These techniques maintain precision and effectiveness while minimizing the intrusive nature of traditional surgical approaches. With these applications you can expect reduced surgical trauma and morbidity, reduction of pain with simplified pain management, fewer post-surgical complications, and accelerated recoveries.

continued...



Minimally Invasive Surgery

Techniques and Applications



Come. Sit. Stay.
Heal...

In this pamphlet you will find:

- Summary of MIS benefits
- Review of rigid endoscopy
- Applications of MIS techniques (how these services might benefit your patients and pets)

This is an excellent tool to supplement the alternatives and information you already provide your clients. The brochure is also a useful mechanism for your staff to achieve greater familiarity with these procedures as well as cultivating a common language to use with each other and with your clientele.

This and other brochures can be found at and downloaded from our website at www.vscdsurgerycenters.com. Simply access the appropriate pamphlet under the drop-down menu or click the link under "disease conditions" on the home page. For complimentary copies of any of our brochures email us any time at deltasurg@yahoo.com.

This issue of the newsletter is dedicated to the memory of Paco, our fearless champion of the bilateral single-session TPLO and fashion collar giant - may his kong be forever by his side. www.pacocollars.com



VSCD Business Office
25-A Crescent Dr. #255
Pleasant Hill, CA 94523

Berkeley

Dublin

Walnut Creek